

# Natural polyphenols target the TGF- $\beta$ /caspase-3 signaling pathway in CCl<sub>4</sub>-induced liver fibrosis in rats

Rania H. Abu-Baih<sup>1</sup>, Asmaa M. A. Bayoumi<sup>2\*</sup>, Ahmed R. N. Ibrahim<sup>2</sup>, Mohamed G. Ewees<sup>3</sup>, Salama R. Abdelraheim<sup>4</sup>

<sup>1</sup> Minia University Hospital, 61519 Minia, Egypt

<sup>2</sup> Department of Biochemistry, Faculty of Pharmacy, Minia University, 61519 Minia, Egypt

<sup>3</sup> Department of Pharmacology and Toxicology, Faculty of Pharmacy, Nahda University, 62513 New Beni Suef, Egypt

<sup>4</sup> Department of Biochemistry, Faculty of Medicine, Minia University, 61519 Minia, Egypt

Received: May 29, 2019; revised: June 19, 2019; accepted: June 25, 2019

## Abstract

**Background/Aims:** Liver fibrosis presents a worldwide problem. There is an increasing interest in the studying of natural compounds with free radicals scavenging capacity to protect against liver fibrosis. This study investigated the actions of resveratrol and curcumin as two natural polyphenols against CCl<sub>4</sub>-induced liver fibrosis.

**Materials and Methods:** Animals were divided into four groups: Normal control group; CCl<sub>4</sub> only group; Res group (resveratrol + CCl<sub>4</sub>); Cur group (curcumin + CCl<sub>4</sub>). Serum ALT and AST were evaluated. Assessment of liver MDA, GSH and catalase was performed. Caspase-3 expression was evaluated by western blotting. Levels of TGF- $\beta$ 1 and TGF- $\beta$ 2 mRNA were determined using qRT-PCR. In addition, liver histopathological sections were examined.

**Results:** We found that serum ALT and AST were elevated by CCl<sub>4</sub>, however, they were significantly reduced by resveratrol and curcumin. Furthermore, CCl<sub>4</sub> induced oxidative stress, stimulated fibrosis and apoptosis. Resveratrol and curcumin significantly attenuated the state of oxidative stress, fibrosis and apoptosis.

**Conclusion:** We conclude that resveratrol and curcumin are natural polyphenols that can protect against liver fibrosis not only via antioxidant, but also via anti-fibrotic and anti-apoptotic potentials.

## Key words

Liver fibrosis, Resveratrol, Curcumin; TGF- $\beta$ , Caspase-3

## 1. Introduction

Liver fibrosis is one of the chronic liver diseases which spread widely especially in the developing countries where it is considered as the seventh leading cause of death around the world [1]. Liver fibrosis may progress to liver failure, hepatocellular carcinoma and cirrhosis which is considered the first leading cause of mortality due to liver disease worldwide [2].

Liver fibrosis is a reversible response which occurs as a result of imbalance between the production of extracellular matrix (ECM) proteins and the breakdown of connective tissue proteins [3]. This imbalance happens due to chronic exposure of liver to injurious factors which include alcohol abuse, viral infections, metabolic diseases, cholestasis and different xenobiotics [4].

In liver fibrosis, hepatic stellate cells (HSCs) are the first effector cells which regulate the deposition of ECM proteins in fibrotic liver [5]. The activated HSCs increased the production of ECM more than its degradation which in turn leads to accumulation and deposition of ECM, the distinctive character of liver fibrosis [6]. In addition, it causes an increase in the production of fibrogenic cytokines including alpha-smooth muscle actin and collagen [7]. After activation of HSCs, many cytokines such as transforming growth factor-beta (TGF- $\beta$ ) and

tumor necrosis factor-alpha (TNF- $\alpha$ ) are secreted for further activation of intracellular signaling pathways and regulation of liver fibrosis [8].

Reactive oxygen species (ROS) are considered the main activator of HSCs through increasing production of pro-fibrogenic cytokines [9]. TGF- $\beta$  is the most potent profibrotic cytokine which is present in three isoforms: TGF- $\beta$ 1, TGF- $\beta$ 2, and TGF- $\beta$ 3 [10,11]. These are responsible for regulation of different biological responses, including cell growth, apoptosis, ECM production and collagen gel contraction [12].

Experimentally, carbon tetrachloride (CCl<sub>4</sub>) toxicity is considered as the best animal model of xenobiotic-induced acute or chronic liver damage through overproduction of ROS [13,14]. The hepatitis induced by long-term exposure of CCl<sub>4</sub> leads to hepatic fibrosis due to hepatocyte necrosis and overproduction of fibrogenic cytokines such as TGF- $\beta$  acting on fibroblasts and activated HSCs [15]. Therefore, scavenging of free radicals and inhibition of lipid peroxidation are a valuable target for prevention of liver fibrosis. Recently, due to the increase of drug side effects, resistance and cost, there is a potent interest in the study of natural compounds with free radicals scavenging capacity to protect against liver fibrosis [16].

\* Correspondence: Asmaa M.A. Bayoumi

Tel.: +20 862347759; Fax: +20 862369075

Email Address: [asmaa\\_bayoumi@mu.edu.eg](mailto:asmaa_bayoumi@mu.edu.eg)

Resveratrol is a natural polyphenol biosynthesized in plant species as a reaction against fungal infection and environmental stress [17]. Resveratrol is known as an efficient anti-inflammatory factor [18] and an antioxidant agent [19]. It has a protective effect against DNA damage [20].

Curcumin is a polyphenol extracted from *Curcuma longa* rhizome. Curcumin can act as a free radical scavenger, and inhibit the activation and nuclear translocation of NF- $\kappa$ B [21,22].

In this study, we aimed to evaluate the possible protective effect of both resveratrol and curcumin against CCl<sub>4</sub> induced liver fibrosis through inhibiting lipid peroxidation (anti-oxidant activity), TGF- $\beta$  production (anti-fibrotic activity) and caspase-3 expression (anti-apoptotic activity).

## 2. Materials and methods

### 2.1. Animals

Thirty-two Wistar adult male rats (200-250 gm body weight) were acclimated for 72 hours before initiating the study, they were housed in stainless steel cages with controlled light and dark cycles and fed a standard diet with water in a controlled temperature ( $25 \pm 1^\circ\text{C}$ ) and humidity ( $50 \pm 5\%$ ) environment. The research was conducted in accordance with the principles for laboratory animal use and care found in the European Community guidelines (EEC Directive of 1986; 86/609/EEC).

### 2.2. Chemicals, anti-bodies and diagnostic kits

Resveratrol and CCl<sub>4</sub> were purchased from Alpha Chemika, India; curcumin was purchased from Merck KGaA, Germany; 1,1–3,3-tetramethoxypropane,5,5-dithiobis-2-nitrobenzoic acid (DTNB), GSH powder and thiobarbituric acid (TBA) were purchased from Sigma Aldrich, St. Louis, MO; Caspase-3 rabbit polyclonal antibody was from Thermo Fisher Scientific, USA;  $\beta$ -actin mouse monoclonal antibody, Horse radish peroxidase (HRP)-coupled goat anti-rabbit and HRP-coupled goat anti-mouse secondary antibodies were from Sigma-Aldrich, USA; ALT and AST reagent kits were purchased from Spinreact, Spain. All chemicals were of high analytical grade.

### 2.3. Experimental design

The rats were randomly divided into four groups, eight rats each: Normal control group; CCl<sub>4</sub> group which was administered CCl<sub>4</sub> only; Res group which was administered resveratrol + CCl<sub>4</sub>; Cur group which was administered curcumin + CCl<sub>4</sub>. Liver fibrosis was induced by 0.8 ml/kg body weight (bw) of CCl<sub>4</sub>: mineral oil (1:1), *i.p.*, twice weekly for six weeks [23]. In Res and Cur groups, animals were pretreated orally with 10 mg/kg bw of resveratrol dissolved in 0.7% carboxy methyl cellulose (CMC) solution [24] and 100 mg/kg bw of curcumin dissolved in 0.5% CMC solution [25], respectively, once daily, starting from day one of CCl<sub>4</sub> injection and continued throughout the whole six weeks.

At the end of the six weeks, animals were anesthetized with 50 mg/kg bw of thiopental [26] and blood samples were collected

from orbital venous plexus in non-heparinized tubes, allowed to stand for 30 min, and then centrifuged at 3000 rpm for 15 min at  $4^\circ\text{C}$  to separate serum which was stored at  $-20^\circ\text{C}$  for determination of liver function parameters; ALT and AST. The rats were then euthanized by cervical dislocation, and the liver tissues were dissected into two sections: one section was stored at  $-80^\circ\text{C}$  for assessment of oxidative stress parameters, RNA and protein analyses; and the other section was fixed immediately in formalin for histopathological examination. Oxidative stress parameters such as malondialdehyde (MDA), reduced glutathione (GSH) and catalase (CAT) activity were measured spectrophotometrically; Caspase-3 expression level was evaluated by western blotting; and the hepatic level of TGF- $\beta$ 1 and TGF- $\beta$ 2 mRNA was determined using real-time PCR (qRT-PCR).

### 2.4. Biochemical determination of ALT and AST levels

To determine liver function, serum ALT and AST levels were assayed colorimetrically using a UV-visible double-beam spectrophotometer by commercially available diagnostic kits according to the manufacturer's instructions [27].

### 2.5. Determination of hepatic reduced glutathione (GSH) content

GSH was measured in liver homogenate according to the method described previously [28]. The principle depends on the reduction of DTNB by the sulfhydryl group of GSH.

### 2.6. Assessment of liver catalase enzyme activity

Catalase activity was measured in liver tissues according to method described previously [29]. The principle depends on the decomposition of hydrogen peroxide by CAT activity.

### 2.7. Determination of hepatic lipid peroxidation

Lipid peroxidation was measured as MDA in the liver homogenates spectrophotometrically at 520–535nm as previously described [30].

### 2.8. Western blotting

Caspase-3 expression was determined by western blotting as previously described [31]. Briefly, liver tissue was homogenized, protein bands were separated by 10% SDS-PAGE and electro-blotted. Membranes were blocked for one hour at room temperature, then they were incubated with rabbit polyclonal antibody to caspase-3 or mouse monoclonal antibody to  $\beta$ -actin overnight at  $4^\circ\text{C}$ . Finally, membranes were incubated with HRP-coupled goat anti-rabbit or HRP-coupled goat anti-mouse secondary antibody for 1 hr. Specific binding was detected using DAB chromogenic kit (*Chongqing Biospes Co., catalogue no. BWR 1069*). Protein bands were analyzed using Image-J software and GraphPad Prism-6 software.

### 2.9. Real-Time PCR

RNA was isolated from liver using Trizol reagent (Invitrogen ThermoFisher, USA). RNA extracts were reverse-transcribed with gene specific primers. Real-Time PCR was performed using Applied Biosyst 7500 fast, Techne (Cambridge) LTD., UK. Reactions were performed as follows: an initial step: cDNA synthesis at 50 °C for 15 min 1 cycle, and Thermo-Start inactivation at 95 °C for 15 min 1 cycle, followed by 40 cycles (denaturation at 95 °C for 15 sec, annealing at 60 °C for 30 sec and extension at 72 °C for 30 sec). Expression was normalized to glyceraldehyde-3-phosphate dehydrogenase (GAPDH) gene expression using the  $\Delta\Delta\text{Ct}$  method. Relative differences in gene expression among groups were determined using the comparative Ct ( $\Delta\Delta\text{Ct}$ ) method, and fold expression was calculated as  $2^{-\Delta\Delta\text{Ct}}$ , where  $\Delta\Delta\text{Ct}$  represents  $\Delta\text{Ct}$  values normalized relative to the mean  $\Delta\text{Ct}$  of control samples.

The primer sequences are as following:

GAPDH sense: 5'GTCGTACCACTGGCATTGTG3'.

GAPDH antisense: 5'CAGCATGGTGACCGTAACAC3'.

TGF- $\beta$ 1 sense: 5'TGCTAATGGTGGACCGCAA3'.

TGF- $\beta$ 1 anti-sense: 5'CACTGCTTCCCGAATGTCTGA3'.

TGF- $\beta$ 2 sense: 5'TTCAGAATCGTCCGCTTCGAT3'.

TGF- $\beta$ 2 anti-sense: 5'TTGTTTCAGCCACTCTGGCCTT3'.

### 2.10. Histopathological examination

Liver was fixed in 10 % buffered formalin solution in normal saline, dehydrated in graded concentrations of ethanol (50-100 %), cleared in xylene and embedded in paraffin. Liver sections (4-5ml) were prepared and stained with hematoxylin-eosin (H&E) dye for photomicroscopic observations [32]. Sections of samples were viewed and evaluated blind to the experiment.

### 2.11. Morphometric study

The histological sections were examined under a light microscope and the extent of necrosis was graded [56] as follows: normal sections (0); minimal centrilobular necrosis (+1); necrosis confined to centrilobular region (+2); extensive necrosis extending from central zone to midzone or further to portal triad (+3).

### 2.12. Statistical analysis

All results were expressed as Mean  $\pm$  Standard Error of Mean (SEM). Statistical analysis was performed by one-way ANOVA test, followed by Tukey's Kramer multiple comparisons test, using GraphPad Prism-6 computer software (San Diego, USA), with values of  $p < 0.05$  considered as statistically significant.

## 3. Results

### 3.1 Effect of CCl<sub>4</sub> alone/with resveratrol or curcumin on liver function

In our study, we observed that CCl<sub>4</sub> caused a significant elevation in ALT and AST levels as compared to normal control group. On the other hand, pretreatment of animals with resveratrol or curcumin significantly decreased the levels of

ALT as well as AST compared to CCl<sub>4</sub> group (**Table 1**). This indicates improvement of liver function on administration of resveratrol or curcumin.

**Table 1:** Effect of CCl<sub>4</sub> alone/with Resveratrol or Curcumin on liver enzymes levels

Groups	ALT (U/L)	AST (U/L)
Normal Control	170.17 $\pm$ 0.3	18.98 $\pm$ 0.21
CCl <sub>4</sub>	275.7 $\pm$ 0.98 <sup>a</sup>	35.5 $\pm$ 0.04 <sup>a</sup>
Resveratrol + CCl <sub>4</sub>	200.53 $\pm$ 0.33 <sup>b</sup>	21.3 $\pm$ 0.02 <sup>b</sup>
Curcumin + CCl <sub>4</sub>	198.2 $\pm$ 0.38 <sup>b</sup>	20.1 $\pm$ 0.06 <sup>b</sup>

- Each value represents the mean of eight experiments  $\pm$  SEM

- Statistical analysis was performed using one-way ANOVA followed by Tukey's Kramer

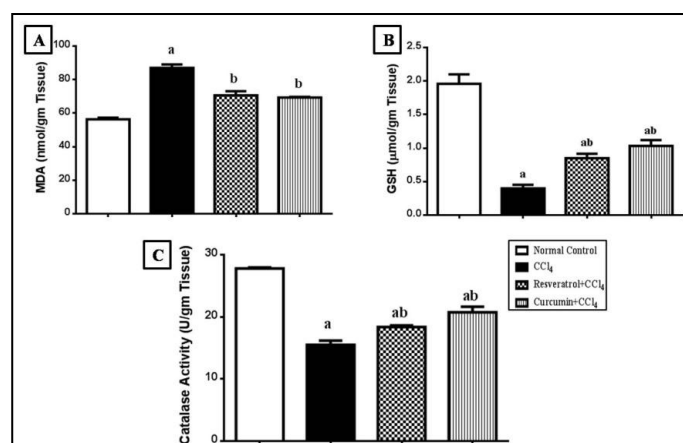
multiple comparisons test

(a) Significantly different from normal control group at  $P < 0.05$

(b) Significantly different from CCl<sub>4</sub> group at  $P < 0.05$

### 3.2. Effect of CCl<sub>4</sub> alone/with resveratrol or curcumin on oxidative stress parameters

In this study, we observed that CCl<sub>4</sub> induced oxidative stress and motivated the production of ROS. CCl<sub>4</sub> significantly increased MDA production to about 163.64 % as compared to normal control group. In addition, CCl<sub>4</sub> significantly decreased hepatic GSH content and CAT activity to about 20 % and 50 %, respectively as compared to normal control group (**Figure 1A, 1B and 1C**).



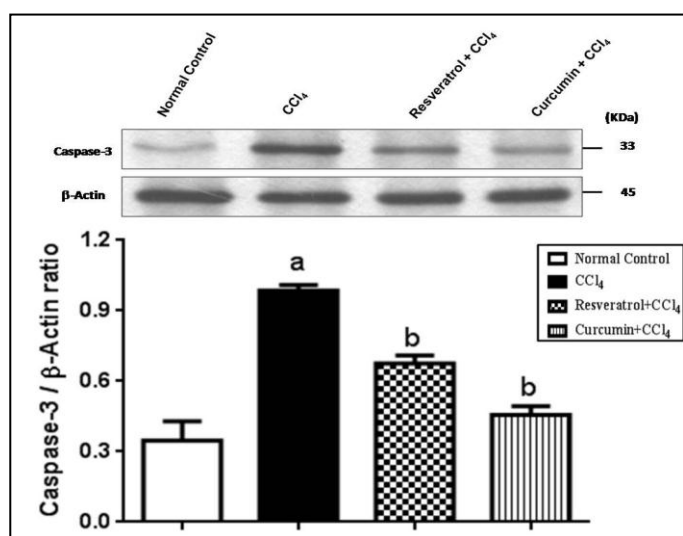
**Figure 1:** Effect of CCl<sub>4</sub> alone/with resveratrol or curcumin on oxidative stress parameters. **A)** Hepatic MDA production, **B)** Hepatic GSH content, **C)** Hepatic CAT activity. **a:** significantly different from normal control group at  $p < 0.05$ ; **b:** significantly different from CCl<sub>4</sub> group at  $p < 0.05$ .

On the other hand, we observed that pretreatment of animals with resveratrol or curcumin significantly decreased MDA productions to about 70.65 % and 68.1 %, respectively. Additionally, significant elevation in hepatic GSH content to about 250 % and 252 % occurred in Res and Cur groups, respectively as compared to CCl<sub>4</sub> group. Side by side, pretreatment of animals with resveratrol or curcumin

significantly increased hepatic CAT activity to about 142.86 % and 143.2 %, respectively compared to CCl<sub>4</sub> group (**Figure 1A, 1B and 1C**).

### 3.3. Effect of CCl<sub>4</sub> alone/with resveratrol or curcumin on the expression of caspase-3 protein in liver tissue

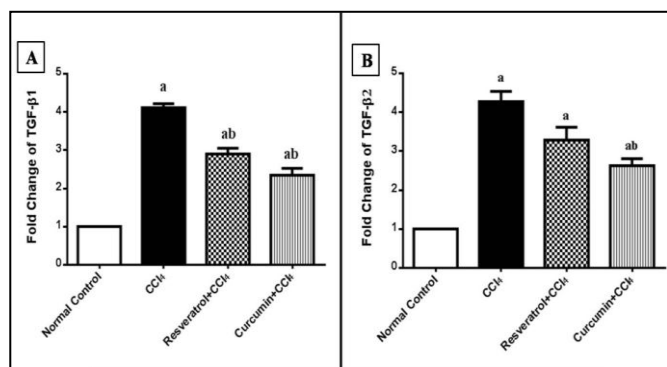
Using western blotting, we found that CCl<sub>4</sub> caused a significant increase in hepatic caspase-3 protein expression as compared to normal control group. On contrary, the expression of caspase-3 protein in hepatic tissue decreased significantly on pretreatment of animals with resveratrol or curcumin as compared to CCl<sub>4</sub> group (**Figure 2**).



**Figure 2:** Effect of CCl<sub>4</sub> alone/with resveratrol or curcumin on hepatic caspase-3 expression determined by western blotting. **a:** significantly different from normal control group at  $p < 0.05$ ; **b:** significantly different from CCl<sub>4</sub> group at  $p < 0.05$ .

### 3.4. Effect of CCl<sub>4</sub> alone/with resveratrol or curcumin on the gene expression of hepatic TGFβ1 and TGFβ2 mRNA

In this work, we found that the gene expression of hepatic level of TGF-β1 and TGF-β2 mRNA was significantly elevated after CCl<sub>4</sub> administration as compared to normal control group. Meanwhile, pretreatment of animals with resveratrol or curcumin significantly reduced the gene expression of both TGF-β1 and TGF-β2 mRNA (**Figure 3A, 3B**).



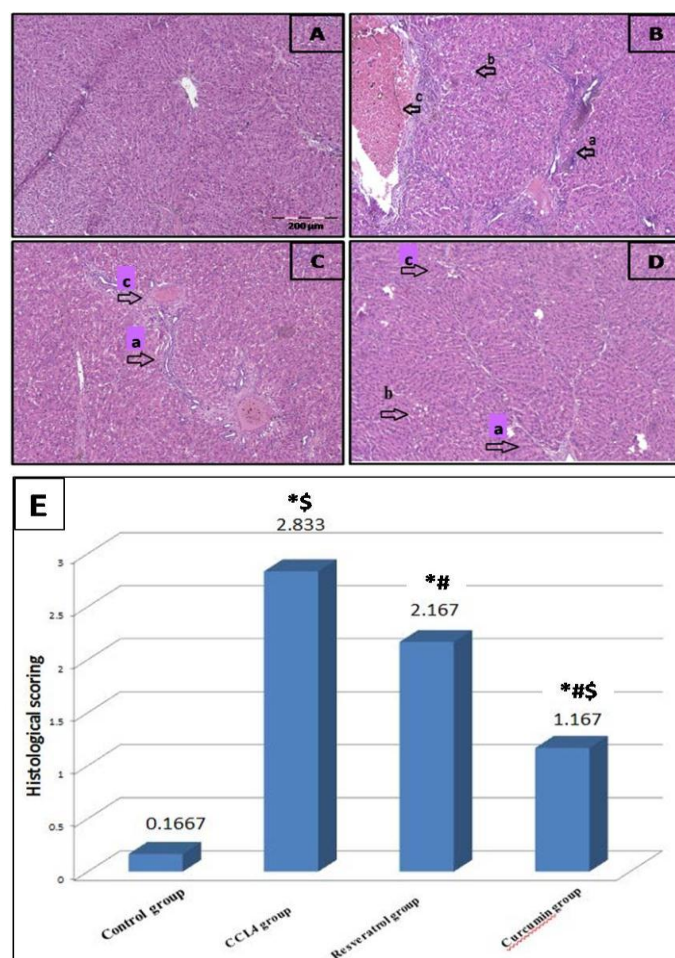
**Figure 3:** Effect of CCl<sub>4</sub> alone/with resveratrol or curcumin on the gene expression of TGF-β in liver tissue determined by qRT-PCR. **A)** TGFβ<sub>1</sub> mRNA, **B)** TGFβ<sub>2</sub> mRNA. **a:** significantly different from normal control group at  $p < 0.05$ ; **b:** significantly different from CCl<sub>4</sub> group at  $p < 0.05$ .

### 3.5 Effect of CCl<sub>4</sub> alone/with resveratrol or curcumin on the histological characters of liver tissue

The hepatic lobules from control group showed normal histological architecture (**Figure 4A**). Liver section derived from CCl<sub>4</sub> group shows disorganization of the lobular pattern with formation of well-defined pseudolobules, fibrosis, fatty changes, and congestion (**Figure 4B**).

Res group and from Cur group showed only a moderate disorganization of the lobular pattern with small areas of fibrosis between hepatocytes and moderate degree of congestion. A less degree of disorganization was observed in Cur group than Res group (**Figure 4C and 4D**).

Histological scoring was performed and the extent of necrosis was graded. Control group showed nearly normal sections (+0.1667); CCl<sub>4</sub> group showed extensive necrosis extending from central zone to midzone or further to portal triad (+2.833); Res group showed necrosis confined to centrilobular region (+2.167); Cur group showed minimal centrilobular necrosis (+1.167) as shown in (**Figure 4E**).



**Figure 4:** Photomicrographs of liver sections. **A)** Control group showing normal histological architecture. **B)** CCl<sub>4</sub> group showing disorganization of the lobular pattern with the formation of well-defined pseudolobules. **C)** Resveratrol group showing moderate disorganization of the lobular pattern with small bands of fibrosis between hepatocytes. **D)** Curcumin group showing moderate congestion and mild disorganization of the lobular pattern. Arrow **a:** fibrosis, **b:** fatty changes, **c:** congestion. H&E X 100. **E)** Bar chart and statistical analysis of histopathological changes. Results represent the mean ± SEM (n = 8). \*: significant difference from control group; #: significant difference from CCl<sub>4</sub> group; \$: significant difference from Resveratrol group,  $p < 0.05$ .

#### 4. Discussion

This study demonstrates anti-fibrotic and anti-apoptotic actions of natural polyphenols such as resveratrol and curcumin against CCl<sub>4</sub> induced liver fibrosis in rats. We observed that CCl<sub>4</sub> caused a significant elevation in ALT and AST and changed histological characters of hepatocytes. These results are in line with previous results [33,34].

We observed that CCl<sub>4</sub> increased oxidative stress where it significantly increased lipid peroxidation and decreased GSH and CAT. These findings confirm previous results [35,36]. This can be explained by the metabolic activation of CCl<sub>4</sub> to reactive radical metabolites; CCl<sub>3</sub><sup>\*</sup> and OOCCL<sub>3</sub><sup>\*</sup> [37]. These radicals attack intracellular macromolecules, causing depletion of antioxidants and increasing lipid peroxidation [38].

Additionally, CCl<sub>4</sub> activates Kupffer cells which promote releasing of cytokines and increase ROS. This can trigger the translocation of NF-κB to nucleus [39] and activation of inflammatory cytokines that enhance cytochrome-c translocation and caspase-3 activation [40,41]. These explanations elucidated the increase in liver caspase-3 by CCl<sub>4</sub>. These results come in line with Kurt *et al.* (2016) who found that CCl<sub>4</sub> significantly increased the expression of caspase-3 in lung tissue in rats [42].

In our study, CCl<sub>4</sub> significantly increased TGF-β1 and TGF-β2 mRNA in liver tissue. This finding was confirmed previously [43]. In liver disease, TGF-β1 is described as a key player in myofibroblast activation [44] and hepatocyte apoptosis [45]. It is clear that oxidative stress plays an important role in initiation of fibrogenesis by increasing harmful cytokines, in particular TGF-β. Therefore, antioxidants are targeting the cause of liver fibrosis and interrupting its progression [46].

We found that resveratrol and curcumin significantly decreased liver ALT and AST and improved histological characters deteriorated by CCl<sub>4</sub>. These results are in line with the results reported by Otuechere *et al.* (2014) who found that curcumin decreased liver enzymes and improved histological characters of liver in rats injected with propanil [47]. Also, It was found previously that resveratrol decreased liver enzymes and improved histological characters in liver fibrosis induced by dimethylnitrosamine in rats [48].

We found that resveratrol and curcumin significantly decreased MDA production and increased hepatic GSH and CAT compared to CCl<sub>4</sub> group. Our results are supported by Abdu and Al-Bogami (2017) who found that resveratrol preserved GSH in ischemia/reperfusion induced oxidative injury in rats [48]. This hepatoprotective effect of resveratrol and curcumin is related to the potent antioxidant activity and ROS scavenging properties of both drugs [49,50].

The ability of resveratrol and curcumin to overcome oxidative stress and decrease ROS production was reflected on the expression of TGF-β1 and TGF-β2 in liver tissue. These findings confirmed the results reported in previous studies which showed the ability of polyphenolic compounds to inhibit the expression of TGF-β [51,52].

One of the important findings of this study is the anti-apoptotic activity demonstrated by the ability of resveratrol and curcumin to decrease the expression of caspase-3 in liver tissue. Our results are in harmony with a previous study which showed that resveratrol could inhibit apoptosis [52]. Moreover, curcumin decreased the expression of caspase-3 in the spleen of diabetic rats [53]. This can be explained by the ability of both drugs to overcome the depletion of antioxidants and lipid peroxidation which prompt the apoptotic pathways [54,55].

By histological scoring, control group showed nearly normal sections; CCl<sub>4</sub> group showed extensive necrosis; Res group showed moderate necrosis confined to centrilobular region; Cur group showed minimal centrilobular necrosis.

The limitations of this article include the necessity of performing a systematic study on the pharmacological action mechanisms of both curcumin and resveratrol. This is to be addressed in the near future.

We conclude that natural polyphenols such as resveratrol and curcumin have a potent protective action against CCl<sub>4</sub>-induced hepatic fibrosis via antioxidant, anti-fibrotic, and anti-apoptotic actions. The recommendation is to put plant polyphenols in the spotlight for anti-fibrotic drug discovery initiatives, attempting to develop more effective and less toxic medications.

#### Disclosure statement

The authors declared no conflicts of interest with respect to the research, authorship, and/or publication of this article.

#### Acknowledgement

We would like to thank **Dr. Azza Hussien** and **Dr. Sara M.N. Abdel Hafez** (Department of Histology, Faculty of Medicine, Minia University) for carrying out the histopathological study and the morphometric study. We are grateful to **Dr. Al-Shaimaa F. Ahmed** (Department of Pharmacology and Toxicology, Faculty of Pharmacy, Minia University) for revising the manuscript.

#### Funding statement

This research did not receive any specific grant from funding agencies in the public, commercial, or not-for-profit sectors.

#### References

- [1] Heidelbaugh JJ, Sherbondy M: Cirrhosis and Chronic Liver Failure: Part II. Complications and Treatment. *Am Fam Physician*. 2006; 74:767–76.
- [2] Zhao J, Zhang Z, Luan Y, *et al.*: Pathological functions of interleukin-22 in chronic liver inflammation and fibrosis with hepatitis B virus infection by promoting T helper 17 cell recruitment. *Hepatology*. 2014; 59:1331–42.
- [3] Tacke F, Zimmermann HW: Macrophage heterogeneity in liver injury and fibrosis. *J Hepatol*. 2014; 60:1090–96.
- [4] Iwaisako K, Brenner DA, Kisseleva T: What's new in liver fibrosis? The origin of myofibroblasts in liver fibrosis. *J Gastroenterol Hepatol*. 2012; 27:65–68.
- [5] Rukkumani R, Aruna K, Varma PS, Menon VP: Curcumin influences hepatic expression patterns of matrix metalloproteinases in liver toxicity. *Ital J Biochem*. 2004; 53:61–66.
- [6] Kisseleva T, Brenner DA: Hepatic stellate cells and the reversal of fibrosis. *J Gastroenterol Hepatol*. 2006; 21:S84–87.
- [7] Hernandez-Gea V, Friedman SL: Pathogenesis of liver fibrosis. *Annu Rev Pathol Mech Dis*. 2011; 6:425–56.
- [8] Friedman SL: Evolving challenges in hepatic fibrosis. *Nat Rev Gastroenterol*

- Hepatol. 2010; 7:425.
- [9] Galicia-Moreno M, Rodríguez-Rivera A, Reyes-Gordillo K, et al.: Trolox Down-Regulates Transforming Growth Factor- $\beta$  and Prevents Experimental Cirrhosis. *Basic Clin Pharmacol Toxicol.* 2008; 103:476–81.
- [10] Inagaki Y, Okazaki I: Emerging insights into transforming growth factor  $\beta$  Smad signal in hepatic fibrogenesis. *Gut.* 2007; 56:284–92.
- [11] Akhurst RJ, Hata A: Targeting the TGF $\beta$  signalling pathway in disease. *Nat Rev Drug Discov.* 2012; 11:790.
- [12] Hirayama K, Hata Y, Noda Y, et al.: The involvement of the rho-kinase pathway and its regulation in cytokine-induced collagen gel contraction by hyalocytes. *Invest Ophthalmol Vis Sci.* 2004; 45:3896–903.
- [13] Ma J-Q, Ding J, Zhang L, Liu C-M: Hepatoprotective properties of sesamin against CCl<sub>4</sub> induced oxidative stress-mediated apoptosis in mice via JNK pathway. *Food Chem Toxicol.* 2014; 64:41–48.
- [14] Kaneko M, Nagamine T, Nakazato K, Mori M: The anti-apoptotic effect of fucoxanthin on carbon tetrachloride-induced hepatotoxicity. *J Toxicol Sci.* 2013; 38:115–26.
- [15] Hussein HS, Hamed MF: Pathological Studies On The Effect Of Curcumin On Liver Fibrosis : Role Of TLR4 , TGF  $\beta$  And Oxidative Stress Hussein S Hussein and Mohamed F Hamed. *Zag Vet J.* 2009; 37:131–46.
- [16] Gangarapu V, Gujjala S, Korivi R, Pala I: Combined effect of curcumin and vitamin E against CCl<sub>4</sub> induced liver injury in rats. *Am J Life Sci.* 2013; 1:117–24.
- [17] Rivera H, Shibayama M, Tsutsumi V, Perez-Alvarez V, Muriel P: Resveratrol and trimethylated resveratrol protect from acute liver damage induced by CCl<sub>4</sub> in the rat. *J Appl Toxicol An Int J.* 2008; 28:147–55.
- [18] Donnelly LE, Newton R, Kennedy GE, et al.: Anti-inflammatory effects of resveratrol in lung epithelial cells: molecular mechanisms. *Am J Physiol Cell Mol Physiol.* 2004; 287:L774–83.
- [19] Cai Y-J, Fang J-G, Ma L-P, Yang L, Liu Z-L: Inhibition of free radical-induced peroxidation of rat liver microsomes by resveratrol and its analogues. *Biochim Biophys Acta (BBA)-Molecular Basis Dis.* 2003; 1637:31–38.
- [20] Leonard SS, Xia C, Jiang B-H, et al.: Resveratrol scavenges reactive oxygen species and effects radical-induced cellular responses. *Biochem Biophys Res Commun.* 2003; 309:1017–26.
- [21] Leclercq IA, Farrell GC, Sempoux C, dela Peña A, Horsmans Y: Curcumin inhibits NF- $\kappa$ B activation and reduces the severity of experimental steatohepatitis in mice. *J Hepatol.* 2004; 41:926–34.
- [22] Reyes-Gordillo K, Segovia J, Shibayama M, Vergara P, Moreno MG, Muriel P: Curcumin protects against acute liver damage in the rat by inhibiting NF- $\kappa$ B, proinflammatory cytokines production and oxidative stress. *Biochim Biophys Acta (BBA)-General Subj.* 2007; 1770:989–96.
- [23] Roderfeld M, Geier A, Dietrich CG, et al.: Cytokine blockade inhibits hepatic tissue inhibitor of metalloproteinase-1 expression and up-regulates matrix metalloproteinase-9 in toxic liver injury. *Liver Int.* 2006; 26:579–86.
- [24] Chávez E, Reyes-Gordillo K, Segovia J, et al.: Resveratrol prevents fibrosis, NF- $\kappa$ B activation and TGF- $\beta$  increases induced by chronic CCl<sub>4</sub> treatment in rats. *J Appl Toxicol An Int J.* 2008; 28:35–43.
- [25] Liu A-C, Zhao L-X, Lou H-X: Curcumin alters the pharmacokinetics of warfarin and clopidogrel in Wistar rats but has no effect on anticoagulation or antiplatelet aggregation. *Planta Med.* 2013; 79:971–77.
- [26] Abdi-Azar H, Maleki S: Comparison of the anesthesia with thiopental sodium alone and their combination with Citrus aurantium L.(Rutaseae) essential oil in male rat. 2014.
- [27] Young DS: Effects of drugs on clinical laboratory tests. vol. 4. AACCC press Washington, DC. 1995; 4vol.
- [28] Sedlak J, Lindsay RH: Estimation of total, protein-bound, and nonprotein sulfhydryl groups in tissue with Ellman's reagent. *Anal Biochem.* 1968; 25:192–205.
- [29] Greenwald RA: Handbook Methods For Oxygen Radical Research: 0. CRC press. 2018.
- [30] Ohkawa H, Ohishi N, Yagi K: Assay for lipid peroxides in animal tissues by thiobarbituric acid reaction. *Anal Biochem.* 1979; 95:351–58.
- [31] Ewees MG, Messiha BAS, Abdel-Bakky MS, Bayoumi AMA, Abo-Saif AA: Tempol, a superoxide dismutase mimetic agent, reduces cisplatin-induced nephrotoxicity in rats. *Drug Chem Toxicol.* 2018:1–8.
- [32] Bancroft JD, Gamble M: Theory and practice of histological techniques. Elsevier Health Sciences. 2008.
- [33] Wang DH, Wang YN, Ge JY, et al.: Role of activin A in carbon tetrachloride-induced acute liver injury. *World J Gastroenterol.* 2013; 19:3802–09.
- [34] Rahmat A, Dar F, Choudhary I: Protection of CCl<sub>4</sub> -Induced Liver and Kidney Damage by Phenolic Compounds in Leaf Extracts of *Cnestis ferruginea* (de Candolle). *Pharmacognosy Res.* 2014; 6:19.
- [35] Said MM, Azab SS, Saeed NM, El-Demerdash E: Antifibrotic mechanism of pinocembrin: Impact on oxidative stress, inflammation and TGF- $\beta$ /Smad inhibition in rats. *Ann Hepatol.* 2018; 17:307–17.
- [36] Shah MD, Gnanaraj C, Haque AE, Iqbal M: Antioxidative and chemopreventive effects of *Nephrolepis biserrata* against carbon tetrachloride (CCl<sub>4</sub>)-induced oxidative stress and hepatic dysfunction in rats. *Pharm Biol.* 2015; 53:31–39.
- [37] Weber LWD, Boll M, Stampfl A: Hepatotoxicity and mechanism of action of haloalkanes: carbon tetrachloride as a toxicological model. *Crit Rev Toxicol.* 2003; 33:105–36.
- [38] Gangarapu V: Combined Effect of Curcumin and Vitamin E against CCl<sub>4</sub> Induced Liver Injury in Rats. *Am J Life Sci.* 2013; 1:117.
- [39] Yu H-J, Lin B-R, Lee H-S, et al.: Sympathetic vesicovascular reflex induced by acute urinary retention evokes proinflammatory and proapoptotic injury in rat liver. *Am J Physiol Physiol.* 2005; 288:F1005–14.
- [40] Loguercio C, Federico A: Oxidative stress in viral and alcoholic hepatitis. *Free Radic Biol Med.* 2003; 34:1–10.
- [41] Chiang-Ting C, Tzu-Ching C, Ching-Yi T, Song-Kuen S, Ming-Kuen L: Adenovirus-mediated bcl-2 gene transfer inhibits renal ischemia/reperfusion induced tubular oxidative stress and apoptosis. *Am J Transplant.* 2005; 5:1194–203.
- [42] Kurt A, Tumkaya L, Yuce S, et al.: The protective effect of infliximab against carbon tetrachloride-induced acute lung injury. *Iran J Basic Med Sci.* 2016; 19:685–91.
- [43] Hafez MM, Hamed SS, El-Khadragy MF, et al.: Effect of ginseng extract on the TGF- $\beta$ 1 signaling pathway in CCl<sub>4</sub>-induced liver fibrosis in rats. *BMC Complement Altern Med.* 2017; 17:1–11.
- [44] Friedman SL: Mechanisms of hepatic fibrogenesis. *Gastroenterology.* 2008; 134:1655–69.
- [45] Michalopoulos GK: Liver regeneration. *J Cell Physiol.* 2007; 213:286–300.
- [46] Bierie B, Moses HL: TGF- $\beta$  and cancer. *Cytokine Growth Factor Rev.* 2006; 17:29–40.
- [47] Otuechere CA, Abarikwu SO, Olateju VI, Animashaun AL, Kale OE: Protective Effect of Curcumin against the Liver Toxicity Caused by Propanil in Rats. *Int Sch Res Not.* 2014; 2014:1–8.
- [48] Abdu SB, Al-Bogami FM: Influence of resveratrol on liver fibrosis induced by dimethylnitrosamine in male rats. *Saudi J Biol Sci.* 2017; 26:201–09.
- [49] Candelario-Jalil E, de Oliveira ACP, Gräf S, et al.: Resveratrol potently reduces prostaglandin E<sub>2</sub> production and free radical formation in lipopolysaccharide-activated primary rat microglia. *J Neuroinflammation.* 2007; 4:25.
- [50] Bruck R, Ashkenazi M, Weiss S, et al.: Prevention of liver cirrhosis in rats by curcumin. *Liver Int.* 2007; 27:373–83.
- [51] Bisht S, Khan MA, Bekhit M, et al.: A polymeric nanoparticle formulation of curcumin (NanoCurc™) ameliorates CCl<sub>4</sub>-induced hepatic injury and fibrosis through reduction of pro-inflammatory cytokines and stellate cell activation. *Lab Investig.* 2011; 91:1383.
- [52] Rivera-Espinoza Y, Muriel P: Pharmacological actions of curcumin in liver diseases or damage. *Liver Int.* 2009; 29:1457–66.
- [53] Hashish H, Kamal R: Effect of curcumin on the expression of Caspase-3 and Bcl-2 in the spleen of diabetic rats. *J Exp Clin Anat.* 2015; 14:18.
- [54] Zhang B, Hirahashi J, Cullere X, Mayadas TN: Elucidation of molecular events leading to neutrophil apoptosis following phagocytosis cross-talk between caspase 8, reactive oxygen species, and MAPK/ERK activation. *J Biol Chem.* 2003; 278:28443–54.
- [55] Guicciardi ME, Gores GJ: Apoptosis: a mechanism of acute and chronic liver injury. *Gut.* 2005; 54:1024–33.
- [56] Tulic, M. K., P. D. Sly, D. Andrews, M. Crook, F. Davoine, S. O. Odemuyiwa, A. Charles, M. L. Hodder, S. L. Prescott, P. G. Holt, and R. Moqbel. 2009. 'Thymic indoleamine 2,3-dioxygenase-positive eosinophils in young children: potential role in maturation of the naive immune system', *Am J Pathol*, 175: 2043-52.